

## Full Length Research Paper

# Ocular findings in patients with head injury

**\*<sup>1</sup>Masila Faith, <sup>2</sup>Kiboi Julius Githinji, <sup>1</sup>Marco Sheila, <sup>1</sup>Njuguna Margaret**

<sup>1</sup>Department of Ophthalmology, College of Health Sciences, University of Nairobi

<sup>2</sup>Department of Surgery-Neurosurgery, College of Health Sciences, University of Nairobi

\*Correspondence Author's Email: faithvata@yahoo.com, j\_kiboi@yahoo.com

Accepted 12<sup>th</sup> May, 2014

The research aim is to describe the ocular and visual findings in patients with head injury. A cross-sectional study of 147 patients with head injury was carried out at Kenyatta National Hospital, Nairobi, Kenya. Participants were recruited consecutively into the study and underwent a thorough ophthalmic and neurosurgical examination. Analysis was done for the age, sex, cause of head injury, in addition to visual and ocular findings. Analysis was done to determine if there was any correlation between ocular findings and the severity of head injury using the Glasgow Coma Scale (GCS), brain CT scan findings and fractures of the skull, orbit and face. The leading causes of head injury were road traffic accidents (44.9%) and assaults (42.2%). The patients comprised 136 males and 11 females. The age ranged from 18 to 77 years (mean=33.7 yrs). Ocular findings were observed in 101(68.7%) cases of head injury. These included lid laceration (8.9%), ecchymosis (36.1%), subconjunctival haemorrhage (13.9%), corneal epithelial defects (16.7%), corneal laceration (0.6%), scleral laceration (0.6%), traumatic cataract (1.1%), vitreous haemorrhage (1.1%), papilloedema (4.4%), optic atrophy (10.6%), retinal haemorrhage (5.6%), pupillary abnormalities (21.7%) and oculomotor nerve palsy (1.1%). Orbital fractures were found in 9 patients. Visual impairment occurred in 52(29.2%) eyes. A positive correlation was seen between severe head injury (GCS <8) and occurrence of ocular signs. There was no correlation observed between ocular findings and findings on CT scan of the brain. There was no correlation seen between ocular findings and fractures of the skull, orbit and face. Various forms of injury occur to the ocular and visual system in patients with head injury.

**Keywords:** head injury, ocular finding, patients, ophthalmic assessment, Kenyatta National Hospital, Kenya

## INTRODUCTION

Head injury is a common cause of death and major disabilities in trauma patients. After moderate to severe injury the disability is frequently characterized by a combination of physical and cognitive defects (Stratton and Gregory, 1994). The visual system is one of the systems involved in traumatic brain injury (TBI). The eye is frequently involved in head trauma due to proximity of the eye to the head as well as due to the neural connections between the eye and the brain.

Many theories have been proposed of how the eye is injured in traumatic brain injury. In penetrating brain injury, there may be physical damage to the visual pathway, visual cortex, and/or other vision-related structures of the brain. In non-penetrating or closed-head injury, displacement, stretching, and shearing forces may damage areas of the brain, including those

associated with vision (Taber et al., 2006). Direct ocular trauma also contributes to the visual dysfunction in patients with head injury.

There has been scanty documentation regarding the ophthalmic manifestations of head injury in many trauma centres. There are several services (neurosurgery, otolaryngology, plastic surgery, general surgery, and ophthalmology) with varied ophthalmologic interest and training, assessing these cases. A number of potential eye injuries may be escaping ophthalmologic assessment (Pelletier et al., 1998). Early diagnosis of visual problems following traumatic brain injury is essential to maximize the overall rehabilitation potential (Sabates et al., 1991). The aim of this study is to describe the spectrum of ocular and visual defects seen in patients with head injury.

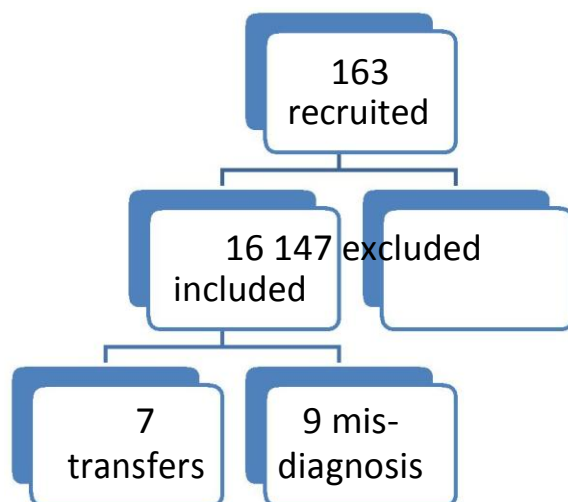


Figure 1. Flow diagram of study patients

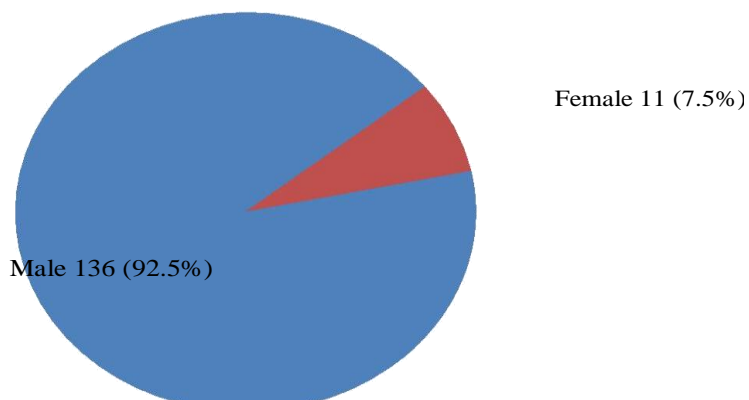


Figure 2. Distribution of patients by sex (n=147)

**MATERIAL AND METHODS**

A cross-sectional study of 147 patients admitted with head injury at Kenyatta National Hospital, Nairobi, Kenya, a national teaching and referral hospital was carried out in April 2012. Patients were recruited consecutively with a diagnosis of head injury by the neurosurgical team on basis of history, neurological findings, admission Glasgow Coma Scale (GCS) and brain CT scan findings. Inclusion criteria consisted of adult patients (18yrs and above) admitted with a diagnosis of head injury within 1 week of injury. Exclusion criteria included patients with head injury less than 18 yrs of age and those presenting with head injury more than 1 week after the injury. Ophthalmic assessment was carried out in all patients within 1 week of admission into the hospital by the ophthalmologist. Visual Acuity was assessed using the LogMAR chart at 3m. A detailed ophthalmic examination was carried out. All ophthalmic and neurological findings were transferred into a questionnaire including the patients’ demographic data and cause of head injury. Analysis was done using

Statistical Package for Social Scientists (SPSS) version 17.0 software. Ocular findings were associated with neurological findings of the patients using Chi square test of associations. Patients were managed according to their respective diagnoses by the neurosurgical and ophthalmologic units.

**RESULTS**

One hundred and sixty-three patients were recruited into the study (Figure 1). Sixteen patients were excluded; 7 patients were excluded as they had head injury for more than 1 week and had been admitted to the surgical ward after transfer from the Intensive Care Unit and 9 patients were excluded as they had coma resulting from medical illness initially thought to be due to head injury. One hundred and forty-seven patients were included in the analysis.

There were 136(92.5%) males and 11(7.5%) females giving a male to female ratio of 12:1(Figure 2). The mean age of the patients was 33.7 years with a range of

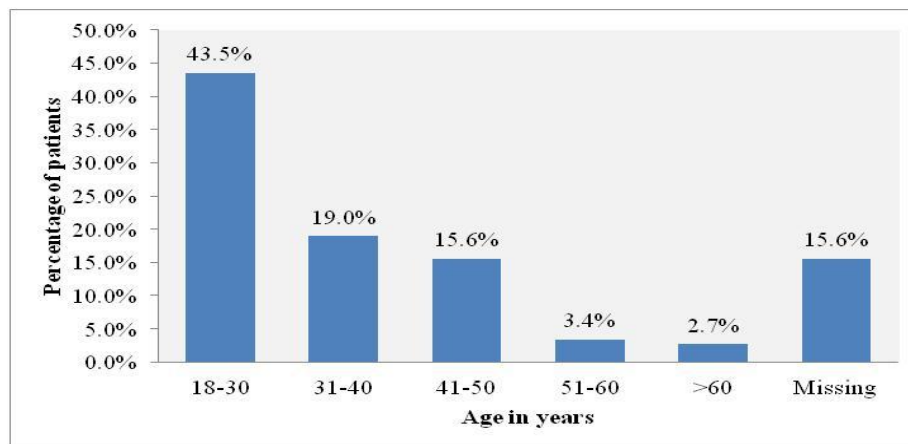


Figure 3. Distribution of patients by age (n=147)

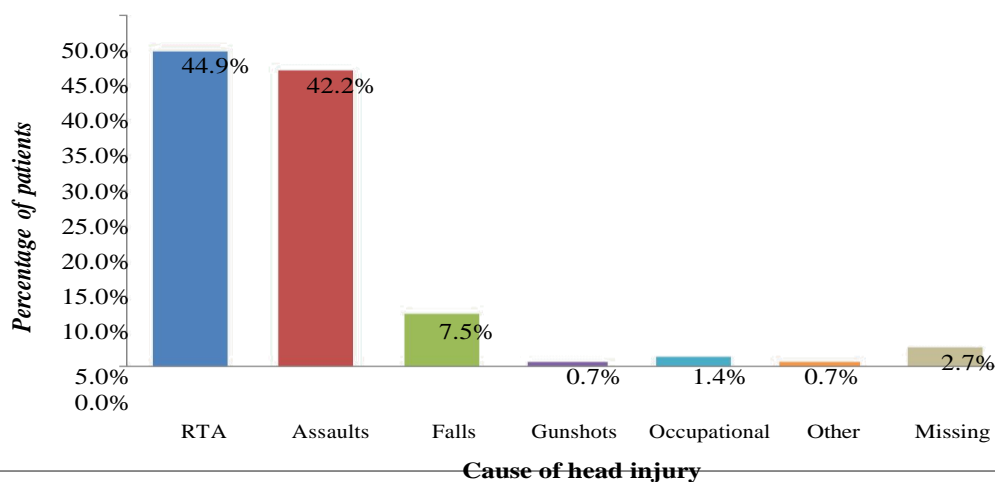


Figure 4. Causes of head injury (n=147)

Table 1. History of ophthalmic complaints (n=89)

Major Ophthalmic Complaint	Frequency	Percentage (%)
Pain	11	12.4
Reduced or loss of vision	7	7.9
Swelling	3	3.4
Other	4	4.5
None	65	73.0
<b>Total</b>	<b>89</b>	<b>100</b>

18 years to 77 years (Figure 3). Majority of the patients were young adults, 64 (43.5%) in the age group 18-30 years.

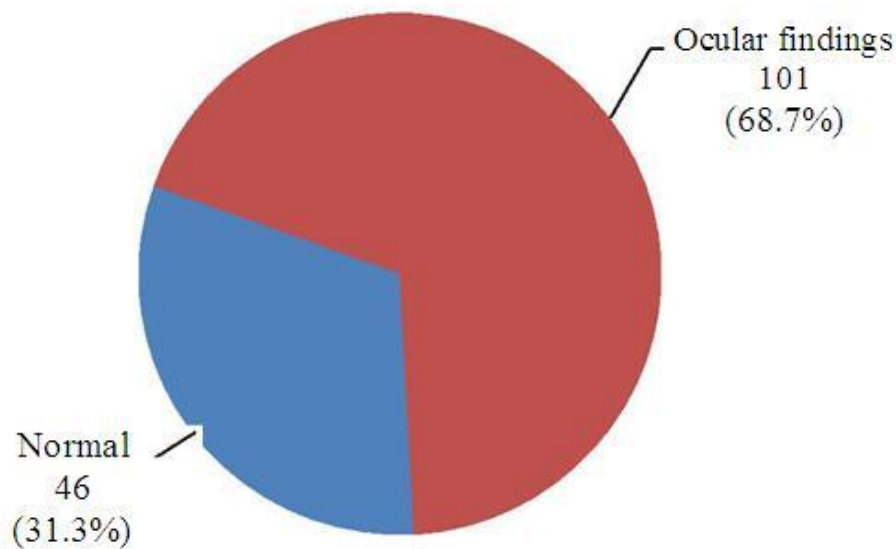
The causes of head injury are shown in Figure 4. The commonest causes of head injury were road traffic accidents (44.9%) and assaults (42.2%). Majority of the assaults occurred in males. In this study only one female

patient had head injury due to assault. The rest of the causes of head injury included occupational injury (1.4%) gunshot injury (0.7%) and others (0.7%).

Ophthalmic complaints were reported in 24 (27%) patients out of 89 patients who were conscious (Table 1). The commonest complaint was eye pain. Other complaints reported were foreign body sensation,

**Table 2** Visual acuity (LogMAR) per eye (n=178 eyes)

VA		Frequency	Percentage (%)
0.0-0.5	(Normal Vision)	126	70.8
<0.5-1.0	(Visual Impairment)	39	21.9
<1.0-1.30	(Severe Visual Impairment)	6	3.4
<1.3-NPL	(Blind)	7	3.9
<b>Total</b>		<b>178</b>	<b>100</b>



**Figure 5.** Prevalence of ocular findings (n=147)

itchiness and tearing.

Visual Acuity was taken in 89 patients (178 eyes) who were conscious. Majority of the eyes, 126 (70.8%) had normal vision. A total of 52 eyes (29.2%) had impaired vision (Table 2).

Ocular findings were present in 101(68.7%) patients with head injury (Figure 5).

Ocular findings were present in 101 patients (202 eyes examined) of whom 180 eyes had findings (Table 3).The commonest findings were in the ocular adnexae with ecchymosis occurring most frequently, in 65 (36.1%) eyes. In the anterior segment, corneal epithelial defects (superficial punctate erosions and epithelial defects) were the most frequent finding and occurred in 30 (16.7%) eyes. Corneal and scleral lacerations occurred in 1 eye (0.6%) each. Traumatic cataract was found in 2 eyes (1.1%). In the posterior segment, findings included one patient who had bilateral vitreous haemorrhage and

retinal findings included papilloedema 8, optic atrophy 19, retinal haemorrhage 10, retinal detachment 1, commotio retinae 2, macula hole/scar 2, choroidal rupture 2.

Among the neuro-ophthalmic complications, pupillary abnormalities were found in 39 eyes. Two patients had oculomotor nerve palsy with restriction of extraocular motility and strabismus. The patients had other features of 3<sup>rd</sup> nerve palsy- ptosis and pupillary dilatation.

Orbital fractures were seen in 9 patients. In our study none of the orbital fractures were associated with enophthalmos or extraocular muscle entrapment.

From our study there is a positive correlation between severe head injury (GCS <8) and occurrence of ocular signs (p value 0.059) (Table 4). However the correlation was a clinically significant association and not statistically significant.

There was no statistically significant association

**Table 3: Ocular Findings per eye (n=180 eyes)**

Ocular Diagnosis	Frequency	Percentage (%)
<b>Ocular Adnexae</b>		
Ecchymosis	65	36.1
Lid laceration	16	8.9
Subconjunctival haemorrhage	25	13.9
Chemosis	13	7.2
Infectious conjunctivitis	20	11.1
<b>Anterior Segment</b>		
Corneal epithelial defects	30	16.7
Corneal laceration	1	0.6
Scleral laceration	1	0.6
Iris sphincter tears	3	1.7
Traumatic cataract	2	1.1
<b>Posterior Segment</b>		
Vitreous haemorrhage	2	1.1
Papilloedema	8	4.4
Optic atrophy	19	10.6
Retinal haemorrhage	10	5.6
Retinal detachment	1	0.6
Comotio retinae	2	1.1
Choroidal rupture	2	1.1
Macula hole/scar	2	1.1
<b>Neuro-ophthalmic</b>		
Pupillary abnormalities	39	21.7
3 <sup>rd</sup> nerve palsy	2	1.1
<b>Orbital Fractures</b>	9	5

**Table 4. Correlation of ocular signs with the severity of head injury (Glasgow Coma Scale)**

Variable	Presence of ocular findings		OR (95% CI)	P value
	Yes	No		
<b>Surgical diagnosis</b>				
<b>GCS 13-15(Mild)</b>	40 (41.2%)	28 (57.1%)	1.0	
<b>GCS 9-12(Moderate)</b>	22 (22.7%)	10 (20.4%)	1.5 (0.6-3.8)	0.342
<b>GCS &lt;8 (Severe)</b>	35 (36.1%)	11 (22.4%)	2.2 (1.0-5.1)	0.059

between ocular findings with the findings on brain CT scan (Table 6).

## DISCUSSION

Head injury is an important public health problem. It is defined as trauma leading to brain injury, skull fractures and scalp injury. It includes open or closed head injuries resulting in impairments in cognition, language, memory,

attention, reasoning, abstract thinking, judgement, problem-solving, sensory, perceptual and motor abilities and behaviour, but it does not include brain injuries that are congenital, degenerative or induced by birth trauma.<sup>5,6</sup> The incidence of head

There was no statistically significant association between fractures of the skull, orbit and face with the ocular findings (Table 6)

injury in the US is 403 per 100 000 head of population..<sup>7,8</sup> In Germany it was 332 cases of TBI per

**Table 5.** Correlation of ocular signs with brain CT scan findings

Variable	Presence of ocular findings		OR (95% CI)	P value
	Yes	No		
Intracranial Haemorrhage	43 (46.2%)	17 (38.6%)	1.4 (0.7-2.8)	0.402
Brain Oedema	29 (31.5%)	9 (20.9%)	1.7 (0.8-4.1)	0.202
Brain Infarctions	3 (3.3%)	1 (2.3%)	1.4 (0.1-14.2)	1.000
Brain Contusions	30 (32.6%)	14 (32.6%)	1.0 (0.5-2.2)	0.995
Pneumocephalus	8 (8.8%)	2 (4.5%)	2.0 (0.4-10.0)	0.498

**Table 6.** Correlation of ocular signs with fractures of the skull, orbit and face

Variable	Presence of ocular findings		OR (95% CI)	P value
	Yes	No		
Skull Base fracture	9 (9.5%)	2 (4.7%)	2.1 (0.4-10.4)	0.502
Calvarial fracture	36 (37.9%)	12 (27.3%)	1.6 (0.7-3.6)	0.221
Orbital fracture	9 (9.7%)	0 (0.0%)	-	0.057
Facial fracture	10 (10.6%)	1 (2.3%)	5.8 (0.7-46.4)	0.097

100 000 head of population per year and in children (younger than 16 years) the incidence was 581 cases of TBI per 100 000 inhabitants.<sup>9</sup> In South Africa, the prevalence of traumatic brain injury was 316 cases per 100 000 per head of population per year (Nell and Ormond-Brown, 1991).

The commonest causes of head injury in our study were road traffic accidents and assaults, followed by falls from a height. Other studies have shown road traffic accidents to be a leading cause of head injury. Severity of head injury has been correlated directly to lack of proper seatbelt or helmet use (Sabates et al., 1991).

In our study, majority of the head injury patients (92.5%) were males. Kulkarni and Pelletier found 97% males and 3% females and 81% males and 19% females, respectively (Pelletier et al., 1998; Kulkarni and Aggarwal, 2005). The higher incidence in males seen in our study and various studies indicate men are more likely to engage in risk taking behaviors and which put them at a higher risk of head injury. Alcohol is a significant contributing factor in men. Since more males operate motor vehicles, a high number of road traffic accidents are as a result of reckless driving, leading to more head injury in this population.

Ophthalmic complaints were reported in 24 (27%) patients in our study. In a study by Brahm et al in the USA, 75.4% of all inpatients (with moderate to severe head injury) had subjective complaints. Among the outpatients (with mild head injury) subjective visual complaints were reported in 75.8%.<sup>12</sup> Other visual complaints that may occur in the patient with head

trauma include difficulty reading, photophobia, visual hallucinations, phosphenes, visual field defects, visual cognition deficits, visual inattention and visual perceptual-motor dysfunction (such as impaired spatial relationships and right-left discrimination problems) (Yanoff and Duker, 2009).

Visual abnormalities that follow head trauma occur commonly and can involve any part of the visual pathway. They may be monocular or binocular. In our study majority of the eyes, 126 (70.8%) had normal vision (LogMAR 0.0-0.5). Brahm et al., 2009 found that of the inpatients (with moderate to severe head injury), 77.8% had a visual acuity of 20/60 or better, 6.3% had visual acuity of 20/70-20/100, 12.7% had a visual acuity of worse than 20/100 and 3.2% had no light perception in both eyes. Of the outpatients (with mild head injury), 98.4% had a visual acuity of 20/60 or better, none of the patients had a visual acuity between 20/70-20/100, 1.6% had a visual acuity worse than 20/100 and no patient had no light perception. This showed a majority of patients in both the inpatient and outpatient populations had normal to near-normal acuities similar to our study.

The prevalence of ocular findings in our study was 68%. Kulkarni and Aggarwal, 2005 found a higher prevalence of ocular involvement of 83.5% in closed head injury patients. Kowal, 1992 found a lower estimate in the range of 30-50% of closed head injury patients who had visual signs and symptoms. Studies show that higher incidences of ocular findings are found when ophthalmologists participate in the examination of head injury patients. This implies that there are certain

ocular defects which may be missed by other medical personnel who examine the eye in head injury patients. Pelletier et al., 1998 showed that data lacking in the visual assessment of head and neck trauma patients were visual acuity, pupillary reaction, motility assessment, lid function, integrity of the globe and funduscopy. Jabaley et al reported the incidence of ocular injury in patients with facial fractures through a retrospective study and a prospective one. In the retrospective study, ophthalmology consultation was decided upon by the admitting plastic surgeon. The results showed 11% had an ocular injury. In the prospective study, all patients with fracture diagnosis were seen by an ophthalmologist, 29% had signs of ocular injury (Jabaley et al., 1975).

Physical ocular trauma is a common finding in head injured patients. It is due to direct trauma to the ocular contents and involves injury to the ocular adnexae, anterior and posterior segments of the globe. Ecchymosis and subconjunctival haemorrhage are the commonest findings seen in the ocular adnexae. Corneal and scleral lacerations, traumatic cataract are seen frequently in the anterior segment. Posterior segment manifestations include vitreous haemorrhage, retinal haemorrhage, retinal detachment, macular hole, optic atrophy all of which were seen in our study.

Among the neuro-ophthalmic complications, pupillary abnormalities are a common finding. Causes of fixed and dilated pupils in the head injury patient include transtentorial/uncal herniation (Hutchinson's pupillary signs), traumatic 3<sup>rd</sup> nerve palsy (which occurred in 2 patients in our study), traumatic mydriasis and orbital blow-out fracture (the latter 2 were not found in our study). In head injury patients causes of pin-point pupils include Horner's syndrome, traumatic miosis, pontine hemorrhage and Hutchinson's pupil (early stages of transtentorial herniation).

Papilloedema is a common neuro-ophthalmic complication. Papilloedema occurring within 48 hours indicates extra or intracerebral haemorrhage and is an indication for immediate surgical measures. Papilloedema occurring after 1 week of head injury is usually due to cerebral oedema.

There was restriction of extraocular motility and strabismus in two patients in our study. Both were due to 3<sup>rd</sup> nerve palsy and the patients had other features of 3<sup>rd</sup> nerve palsy- ptosis and pupillary dilatation. Ocular motor cranial nerve palsy leading to motility disorders is a frequently encountered neuro-ophthalmic complication. The cranial nerves are susceptible to injury because of their long course at the base of the skull. In a study by Kowal (1992), 70 of 164 patients with head injury had cranial nerve palsies, 16 of these had third nerve palsy, 38 had fourth nerve palsy and 16 had sixth nerve palsy. Accurate ocular motility assessment within the first few hours of head injury is not possible with patients in coma. Many signs and symptoms like third nerve misdirection arise a few months after trauma (Smith, 19-

66). Lagophthalmos may occur in the head injury patient due to facial nerve palsy. In fractures of the base of the skull the most common cranial nerve palsy is ipsilateral facial nerve paralysis of the lower motor neuron type. We did not find any patient with facial nerve paralysis in our study.

Strabismus occurs in head injury due to ocular motor cranial nerve palsies or injury to extraocular muscles eg muscle entrapment in orbital fractures. Ciuffreda (2007) found strabismus in 25%. In a study by Kowal, 10 patients had exotropia and 3 had esotropia (Kowal, 1992). Esophoria and exotropia are a common sequelae of head trauma. Binocular single vision may be lost after a head injury, with the breakdown of a latent phoria or loss of the normal physiological fusion of the image presented to each eye (Yanoff and Duker, 2009).

There was no patient who had diplopia, proptosis or nystagmus in our study. Diplopia is a finding frequently encountered in head injury patients. Patients may complain of double vision after discharge from hospital as seen in other studies and it is possible that the head injury patients seen in this study may present later with diplopia after discharge from hospital. In a study by Odebode (2005) four patients complained of double vision, shortly after discharge from the hospital. In a study by Kulkarni, seven patients sought ophthalmic opinion for diplopia within a month of being discharged after their head injury (Kulkarni and Aggarwal, 2005). Most cases of diplopia resolve spontaneously in 6-12 months after the head trauma.

Oscillopsia is a symptom that may occur in the head injury patient. Nystagmus in head injury may occur as a result of internuclear ophthalmoplegia. It may also result from trauma to the optic chiasm which simulates a pituitary region tumor with see-saw nystagmus.

Optic atrophy was seen in 19 eyes in our study, which is an indicator of optic neuropathy. It is likely that the optic atrophy was pre-existing prior to the head trauma. Kowal, 1992 reported severe optic atrophy in 9 patients (who had visual acuities of 6/60 to no light perception with marked disc pallor) and mild optic atrophy in 33 patients (who had acuities better than 6/12).<sup>14</sup> Moster et al., 1999 reported traumatic optic neuropathy in 18%. Traumatic optic nerve damage may result from direct trauma to the nerve as a result of mechanical compression from a fracture fragment or indirect damage from oedema or ischaemia. Spontaneous improvement occurs in 15-33%. If due to mechanical compression from fracture fragment, CT scan is good for diagnosis as it reveals bony fragments and surgical decompression may be undertaken via a intranasal or trans-ethmoidal or trans-sphenoidal approach. If due to indirect damage from edema or ischemia, MRI is better for diagnosis. High dose steroids have been advocated due to their antioxidant effect and to maintain perfusion in indirect damage.

In our study, there was no patient with cerebral(cortical) blindness unlike Banks et al., 2002

Who reported cortical blindness in 0.4-0.6%.

Orbital fractures were seen in 9 patients. In our study none of the orbital fractures were associated with enophthalmos or extraocular muscle entrapment. There was no orbital blow out fracture seen in our study. None of the orbital fractures were associated with globe rupture. Odebode reported globe ruptures in 2 patients with concomitant comminuted fracture of the orbit (Odebode et al., 2005). Optic canal fracture often associated with basilar skull fracture can produce an optic neuropathy.

From our study there is a positive correlation between severe head injury (GCS <8) and occurrence of ocular signs (p value 0.059). However the correlation was a clinically significant association and not statistically significant. A study by Odebode showed nearly half of the ocular and visual injuries occurred in mildly head-injured patients with GCS of 13–15. Severe ocular injury was associated with severe head injury whose GCS was less than or equal to 8 on admission (Odebode et al., 2005).

There was no statistically significant association between ocular findings with the findings on brain CT scan. There was no statistically significant association between fractures of the skull, orbit and face with the ocular findings. A study with a larger sample size could possibly show an association between ocular findings and neurological findings.

Comprehensive examination of the patients with head trauma was limited due to the patients' consciousness level. In patients with markedly reduced levels of consciousness, some aspects of the ocular examination were not carried out such as visual acuity, assessment of strabismus, nystagmus and diplopia test. There was difficulty or inability to obtain ophthalmic history in some moderate to severe head injury patients.

The visual system impacts all aspects of life. Rehabilitation of the head injury patient is much more difficult if the visual system is not efficient. Head injury patients may be difficult to examine because of cognitive and communication disorders. Multiple examinations may be needed to assess fully a brain-injured patient. A complete assessment may include evaluation of the eye, refraction, and examination of ocular motility, accommodation, vergence, stereopsis, visual perception, and visual fields (Falk and Aksionoff, 1992). Vision examinations and treatment may facilitate TBI patient rehabilitation including reading, speech and language deficits, vestibular function, mobility, driving, and other activities in which the visual system plays a role (Karen, 2009).

## CONCLUSION

Various forms of injury occur to the ocular and visual system in patients with head injury.

## RECOMMENDATION

There should be a detailed early ophthalmological assessment in all patients with head injury.

## REFERENCES

- Stratton Margaret C, Gregory Robert J (1994). After traumatic brain injury: a discussion of Consequences *Brain Injury*, 8(7):631-645.
- Taber KH, Warden DL, Hurley RA (2006). Blast-related traumatic brain injury: what is known? *J. Neuropsychiatr. Clin. Neurosci.* 18:141–5.
- Pelletier C, Jordan DR, Braga R (1998). Assessment of ocular trauma associated with head and neck injuries. *J. Trauma* 44(2):350-49.
- Sabates NR, Gonce MA, Farris BK (1991). Neuro-ophthalmological findings in closed head trauma. *J. Clin. Neuro-Ophthalmol.* 11:273-277.
- Brain resource information network. *About traumatic brain injury*. Available online at: <http://www.tndisability.org/brain/About-traumatic-brain-injury.php>, accessed 15 May 2011.
- Individuals with Disabilities Education Act: *Special education lawyers protecting your child educational right. Disabilities under I.D.E.A.* Available online at: <http://www.specialeducationlawyers.info/disabilities.htm>, accessed 15 May 2011.
- Langlois JA, Rutland-Brown W, Thomas KE (2010). Traumatic brain injury in the United States: *Emergency department visits, hospitalizations, and deaths*. Available online at: [www.cdc.gov/ncipc/pub-res/TBI\\_in\\_US\\_04/TBI%20in%20the%20US\\_Jan\\_2006.pdf](http://www.cdc.gov/ncipc/pub-res/TBI_in_US_04/TBI%20in%20the%20US_Jan_2006.pdf), accessed 6 July 2010.
- Keris V, Lavendelsi E, Macane I (2007). Association between implementation of clinical practice guidelines and outcome for traumatic brain injury. *World J. Surg.* 31: 1354– 1357.
- Eckhard R, Klaus V, Paul W (2010). Head injury in Germany: A population-based prospective study on epidemiology, causes, treatment and outcome of all degrees of head-injury severity in two distinct areas *Brain Injury*, November 2010; 24(12):1491–1504
- Nell V, Ormond-Brown S (1991). Epidemiology of traumatic brain injury in Johannesburg– II Morbidity, Mortality and Etiology, *Social Science Medicine*, 33, (3): pp 289 – 296.
- Kulkarni AR, Aggarwal SP (2005). Ocular manifestations of head injury: A clinical study. *Eye (London)*, 19(12):1257-63.
- Karen D (2009). Brahm. Visual Impairment and Dysfunction in Combat-Injured Service members With Traumatic Brain Injury. *Optometry and Vision Science.* 86(7PP): 817–825
- Yanoff M, Duker JS (2009): *Ophthalmology* 3<sup>rd</sup> Edition.
- Kowal L (1992). Ophthalmic manifestations of head injury: *Austra New Zealand J Ophthalmol.* 20: 35–40.
- Jabaley ME, Lerman M, Sanders HJ (1975). Ocular injuries in orbital fractures: a review of 119 cases. *Plast Reconstr Surg.* 1975;56:410-417.
- Smith JL (1966). Some neuro-ophthalmological aspects of head trauma. *Clin Neurosurg.* 13:181–196.
- Ciuffreda KJ, Kapoor N, Rutner D, Suchoff IB, Han ME, Craig S (2007). Occurrence of oculomotor dysfunctions in acquired brain injury: a retrospective analysis. *Optometry*, 78:155–61.
- Odebode TO, Ademola-Popoola DS, Ojo TA Ayanniyi AA (2005).. Ocular and visual complications of head injury. *Eye*, 19:561–566.



- Moster ML, Volpe NJ, Kresloff MS (1999). Neuro-ophthalmic findings in head injury. *Neurol.* 52(2):A23.
- Banks M, Lessell, Simmons MD (2002). Neuro-ophthalmology and Trauma: *Int Ophthalmol Clin. Ocular Trauma.* 42(3): 1–12.
- Falk NS, Aksionoff EB (1992). The primary care optometric evaluation of the traumatic brain injury patient. *J. Am. Optom Assoc.* 63:547-553.